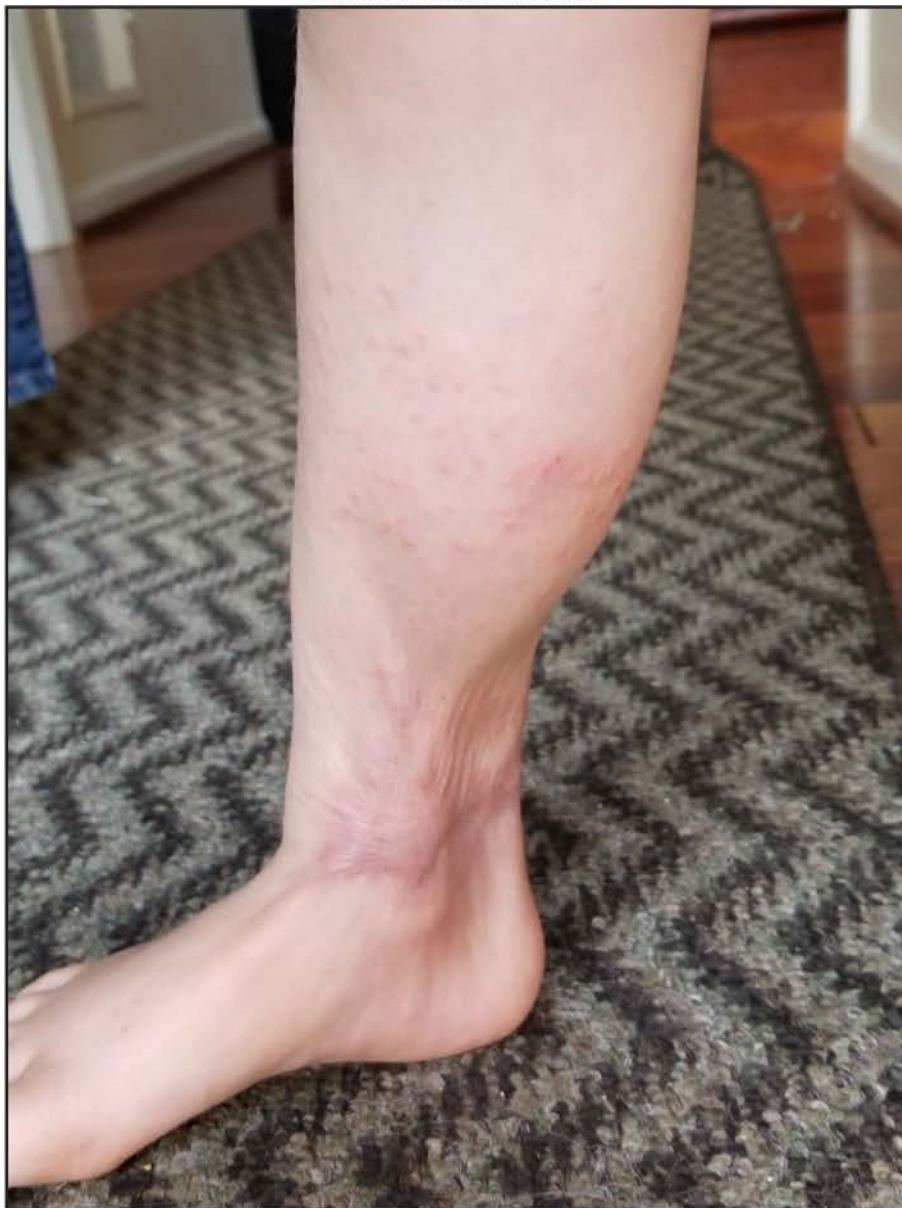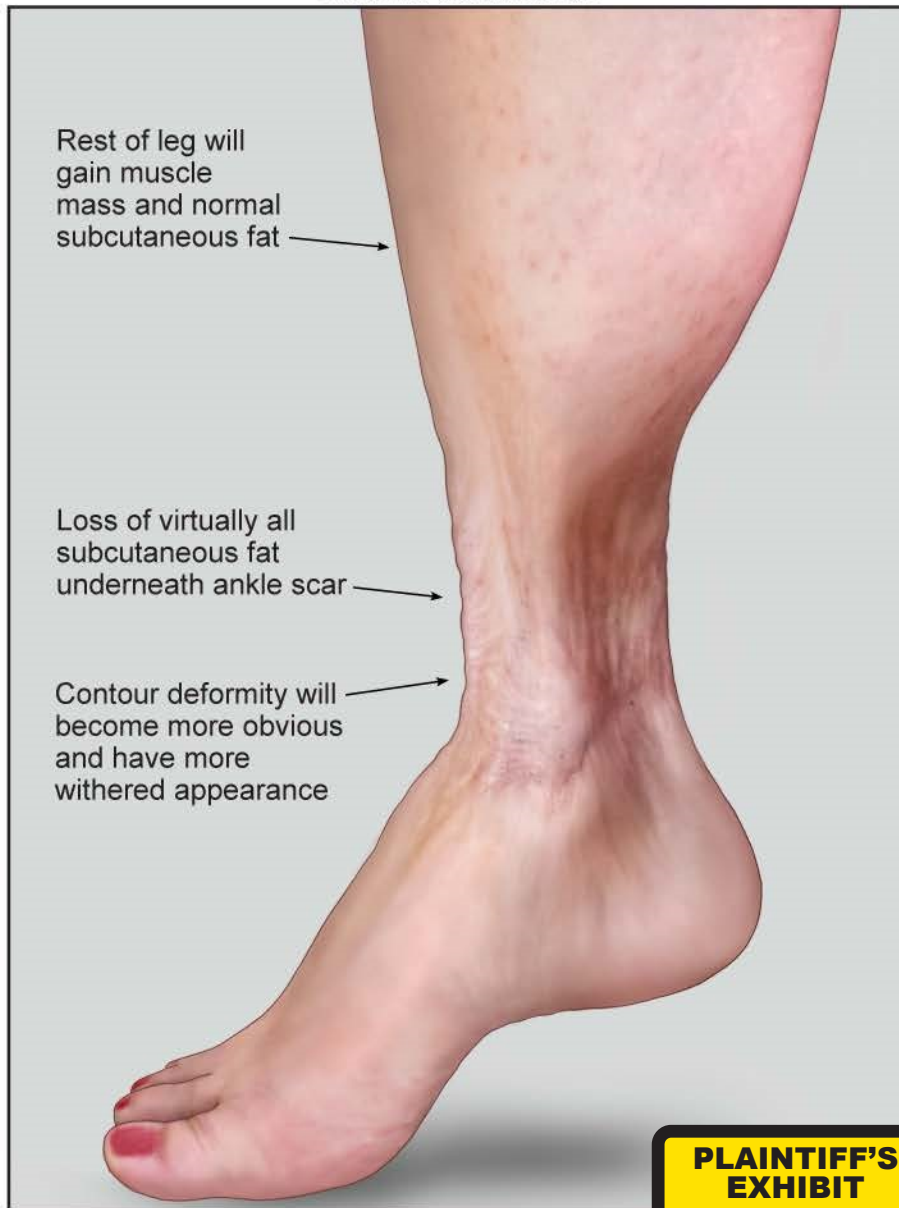


Ankle as Young Adult

Current Condition



Future Condition



Rest of leg will gain muscle mass and normal subcutaneous fat →

Loss of virtually all subcutaneous fat underneath ankle scar →

Contour deformity will become more obvious and have more withered appearance →